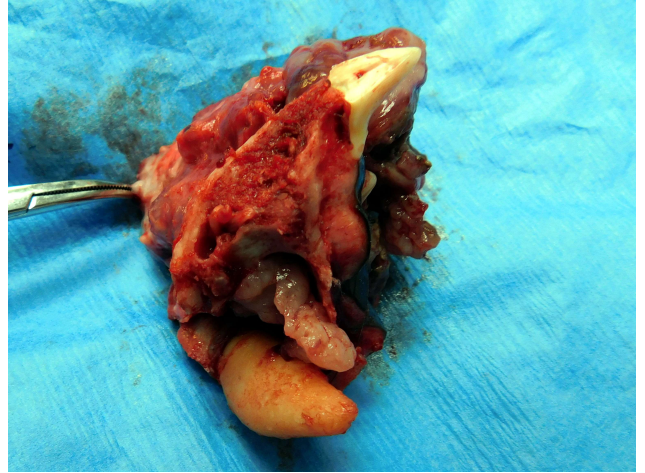
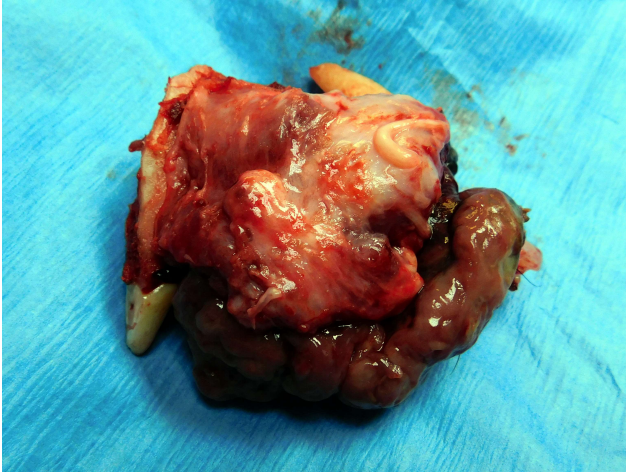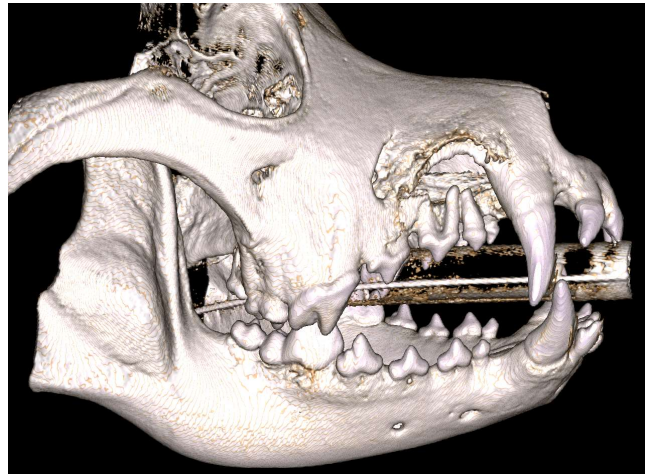
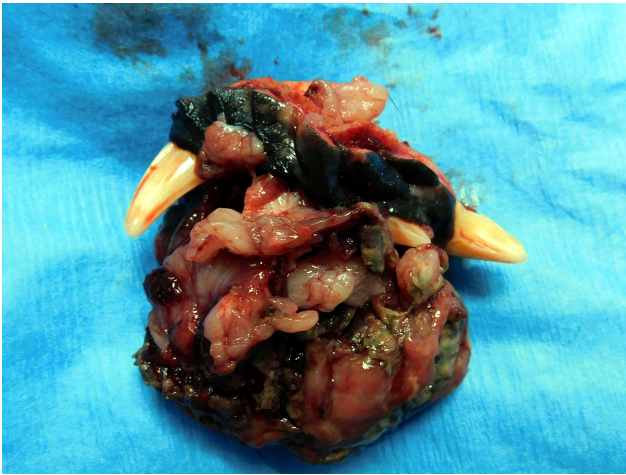


Benji (25605) 4-27-2021



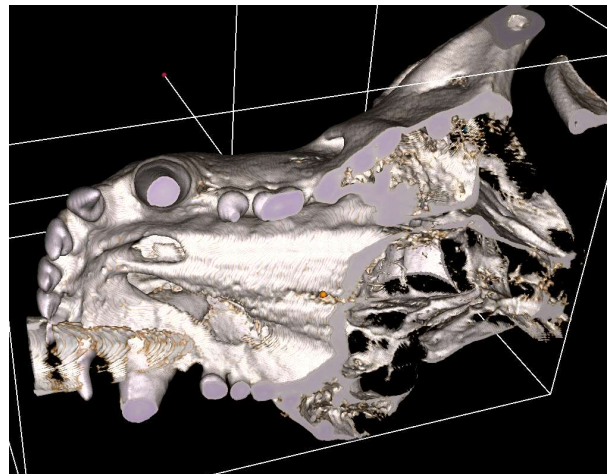
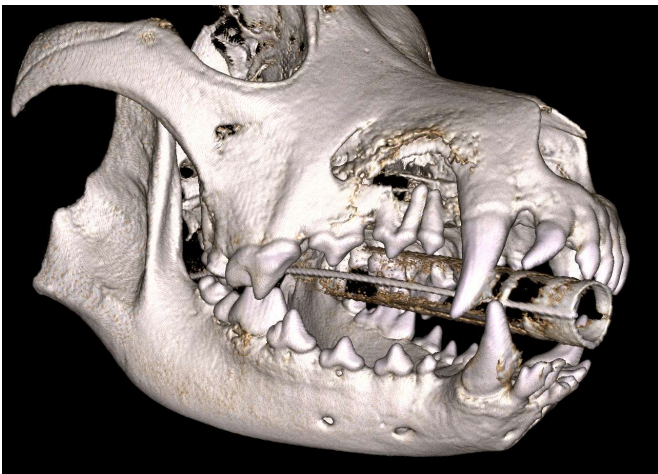
Oral Mass (104-107)

Oral Mass (104-107)



Oral Mass (104-107)

CT
Before Oral Mass (104-107)

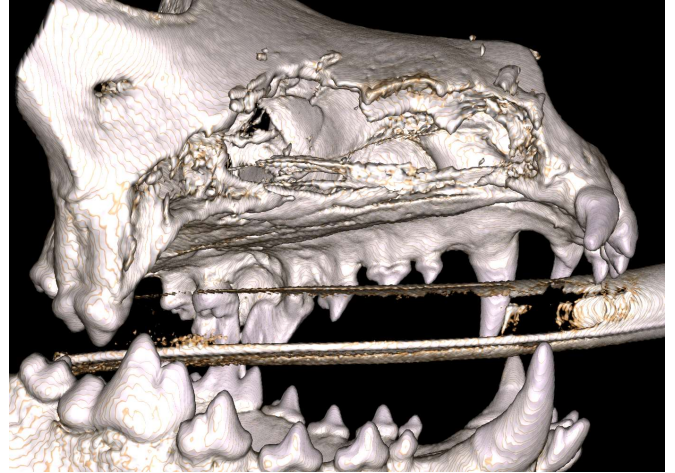
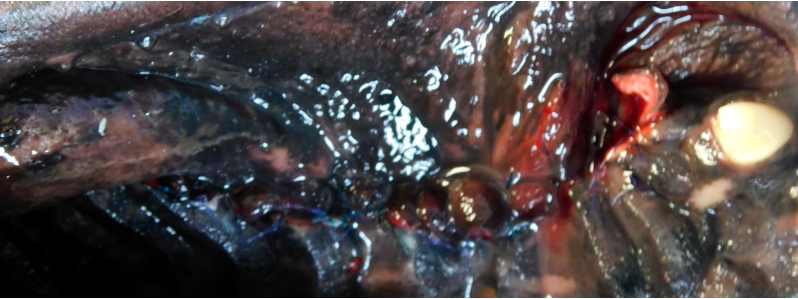


CT
Before Oral Mass (104-107)

CT
Before Oral Mass (104-107)

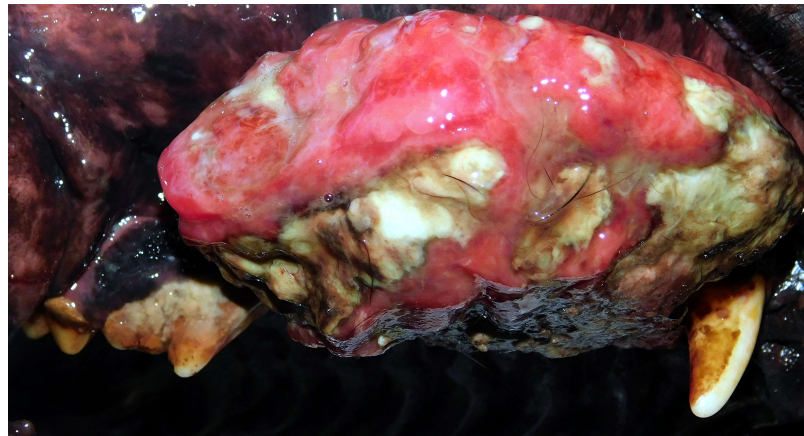
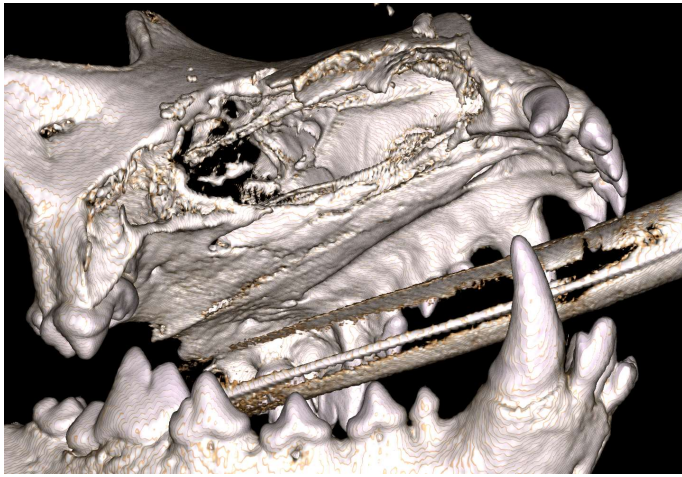All Pets Dental

Benji (25605) 4-27-2021



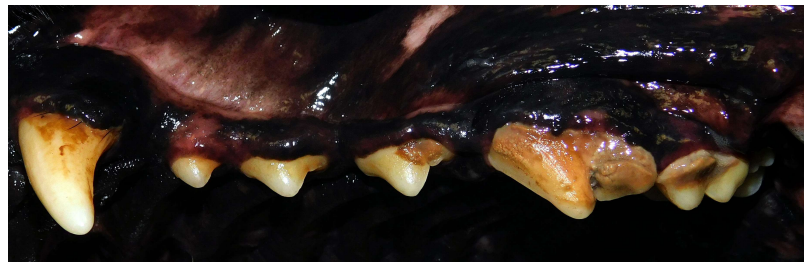
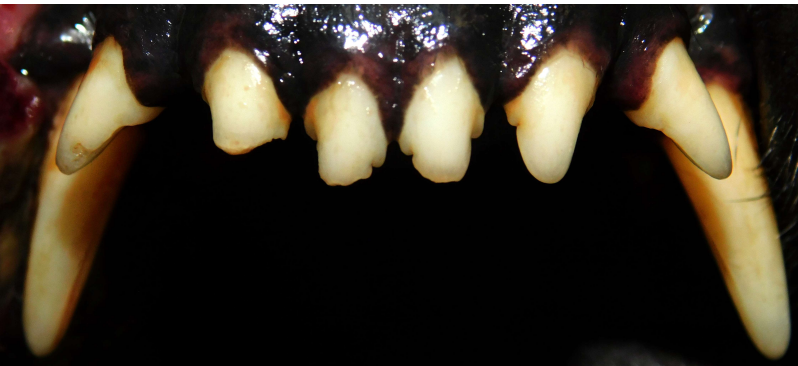
After Biopsy of Oral Mass

CT
After Biopsy of Oral Mass



CT
After Biopsy of Oral Mass

Right Maxilla

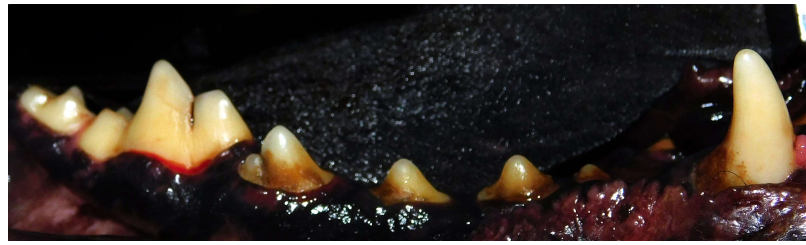


Maxillary Incisors

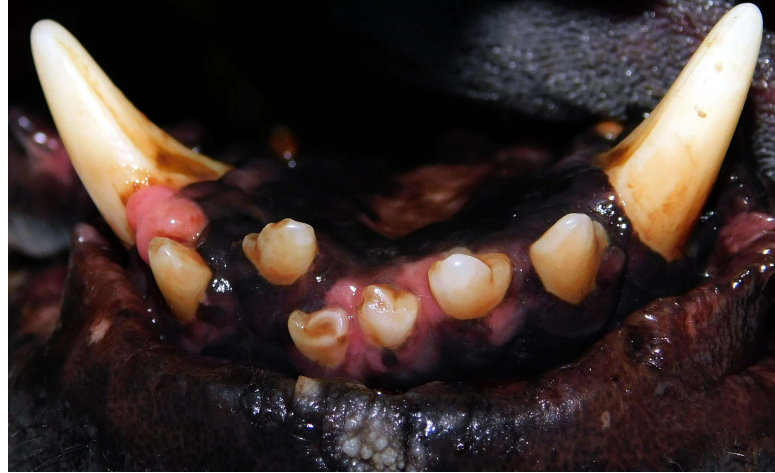Left Maxilla

All Pets Dental

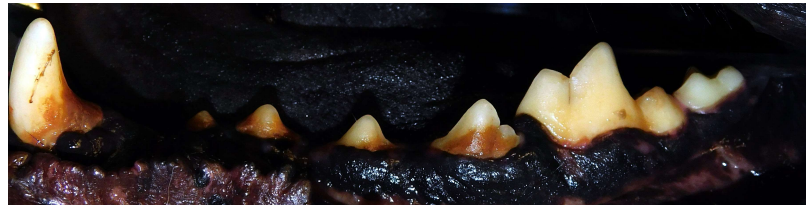
Benji (25605) 4-27-2021



Right Mandible



Mandibular Incisors



Left Mandible

All Pets Dental