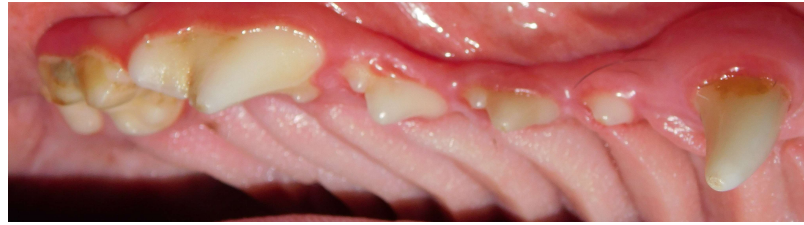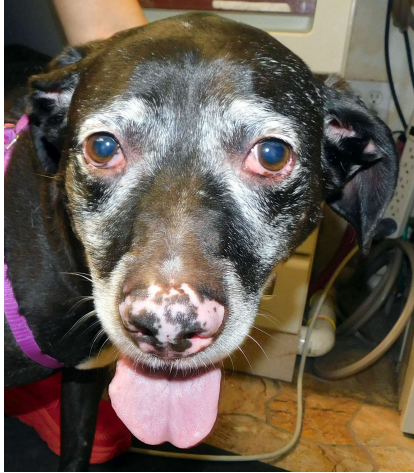

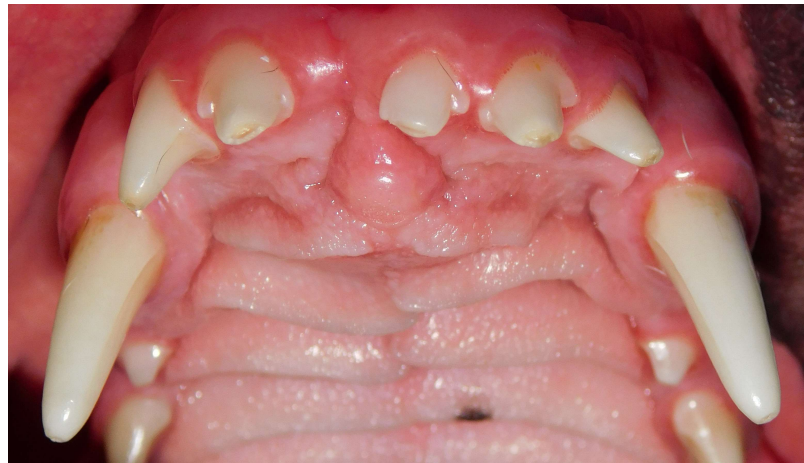
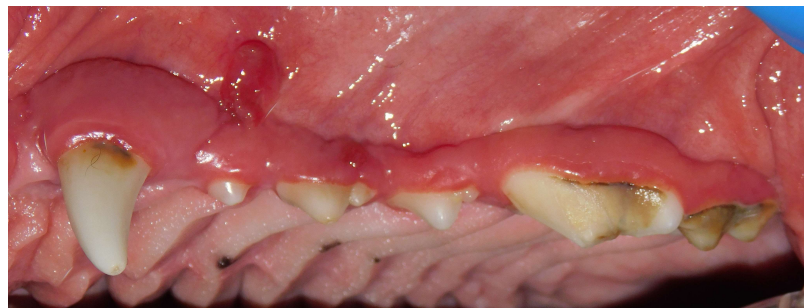Penny (25540) 04-15-2021



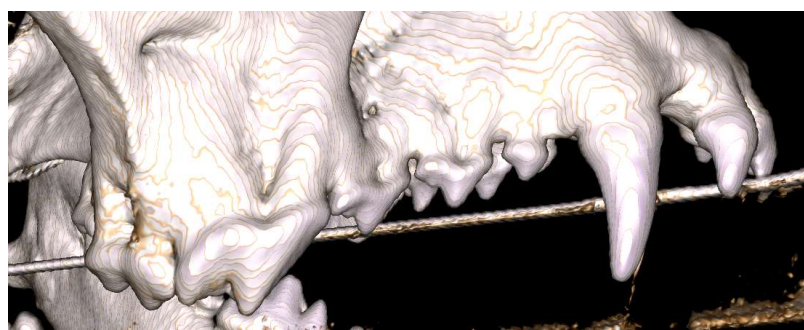
Right Maxilla



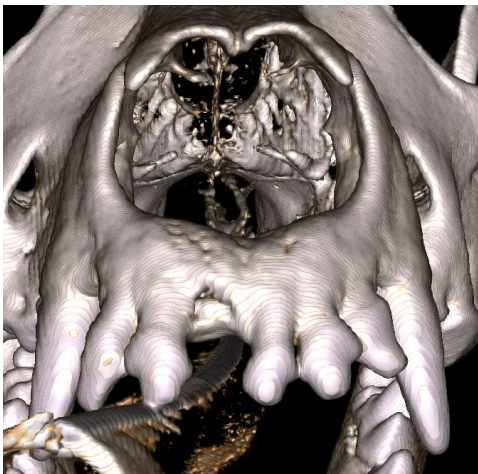
Maxillary Incisors



Left Maxilla



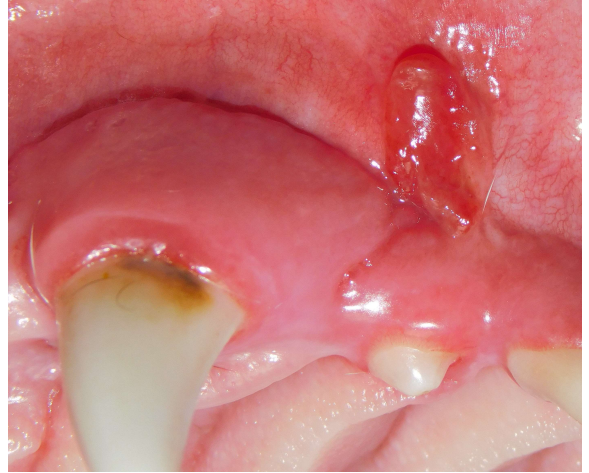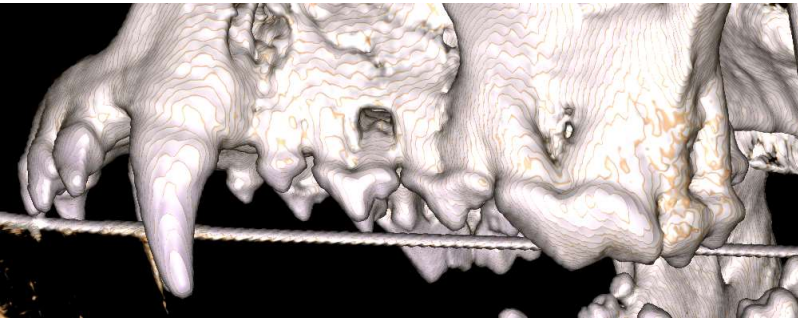
CT
Right Maxilla



CT
Maxillary Incisors

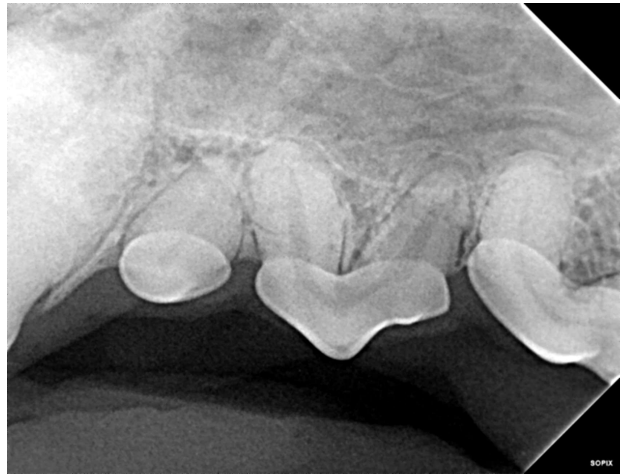
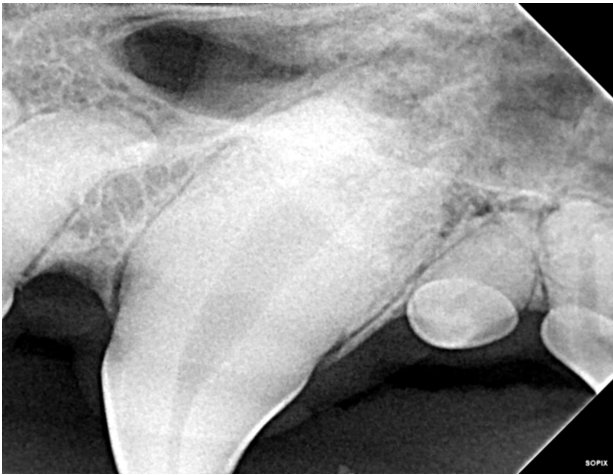
All Pets Dental

Penny (25540) 04-15-2021



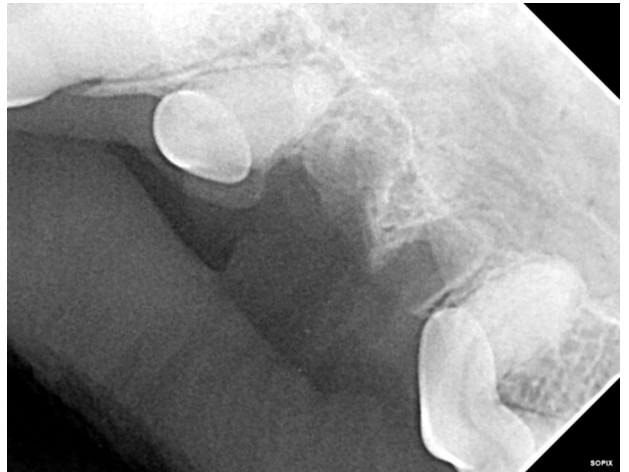
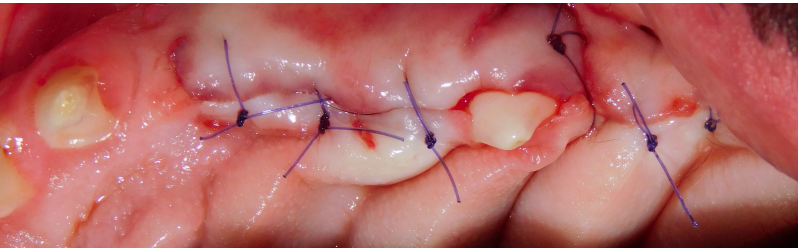
CT
Left Maxilla

Left Canine



X-ray
Left Maxilla

X-ray
Left Maxilla

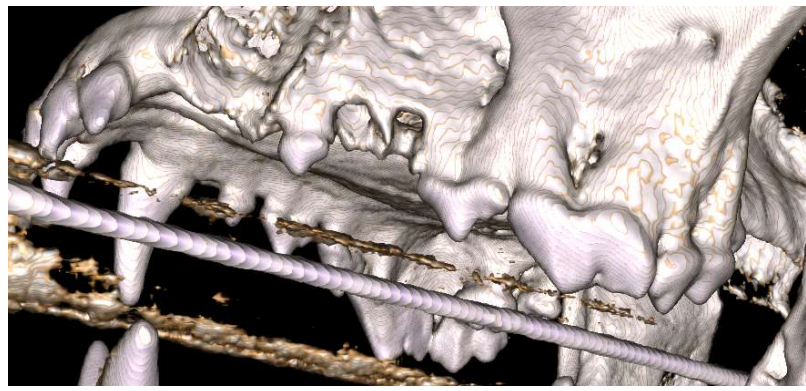


After Oral Surgery

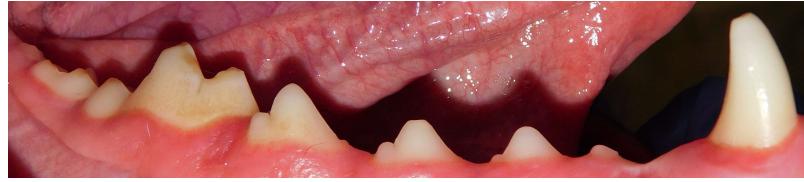
X-ray
After Oral Surgery

All Pets Dental

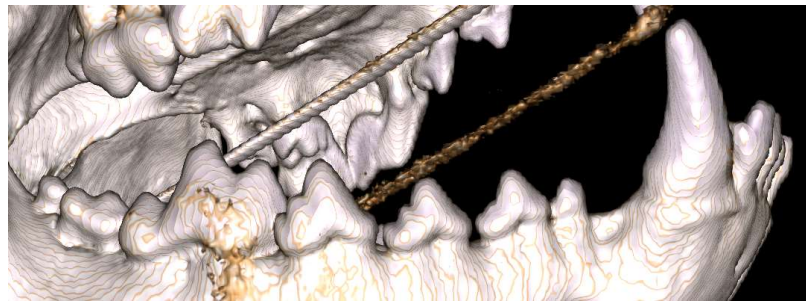
Penny (25540) 04-15-2021



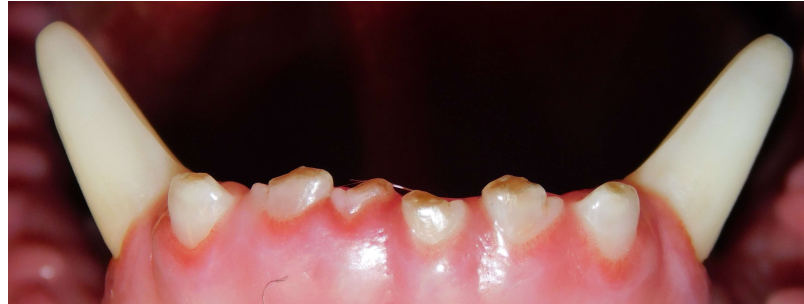CT
After Oral Surgery



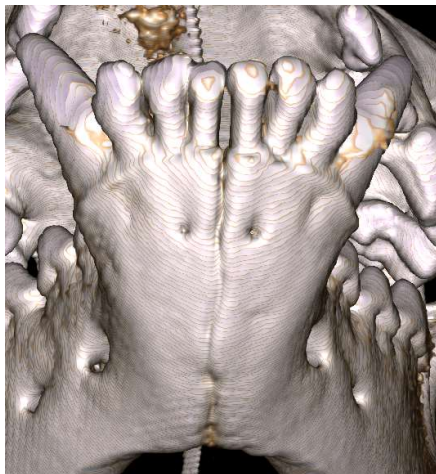
Right Mandible



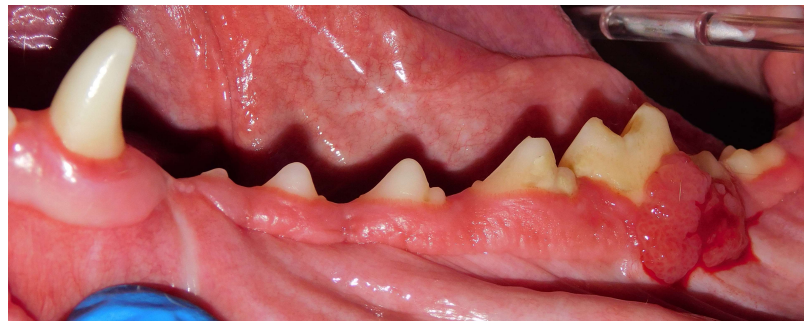CT
Right Mandible



Mandibular Incisors



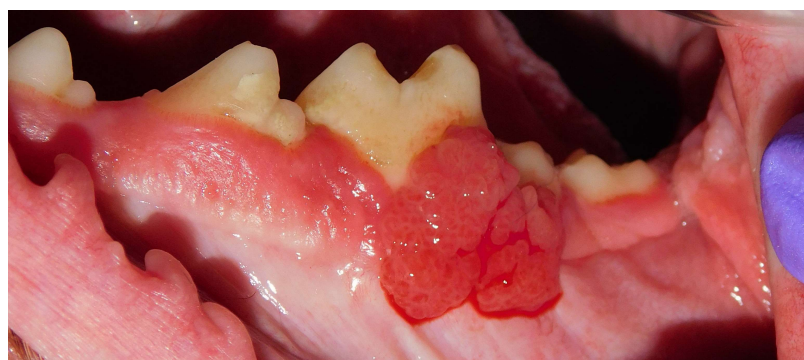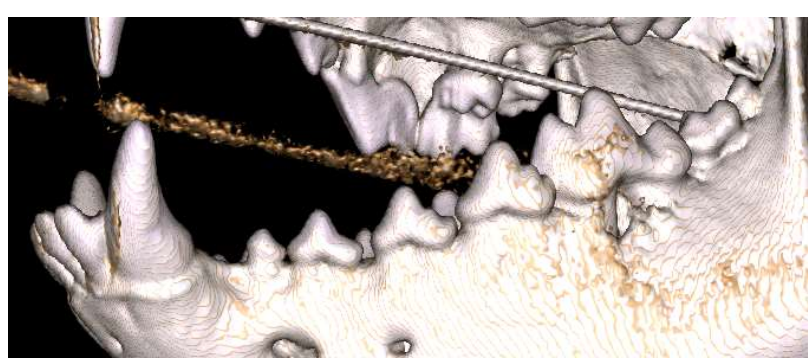
CT
Mandibular Incisors



Left Mandible

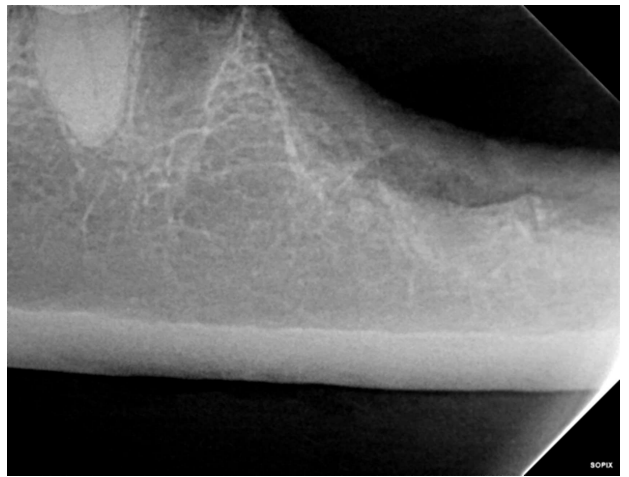
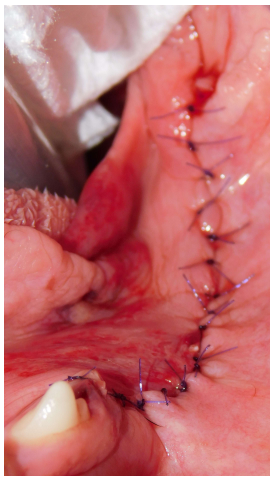
All Pets Dental

Penny (25540) 04-15-2021



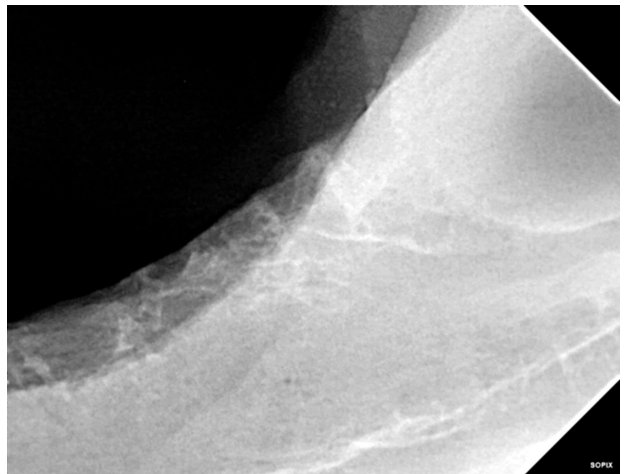
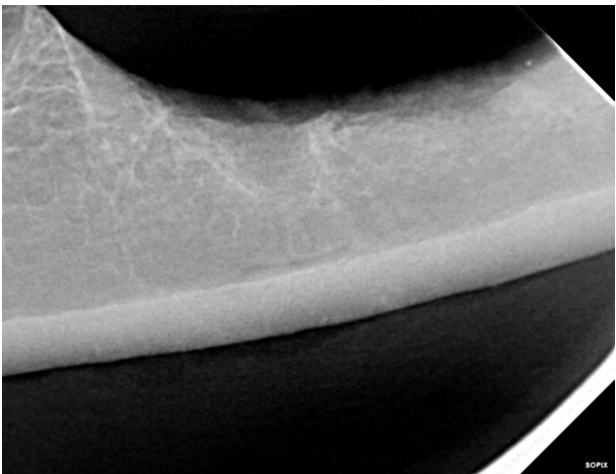
CT
Left Mandible

Oral Mass 309



After Oral Surgery

X-ray
After Oral Surgery

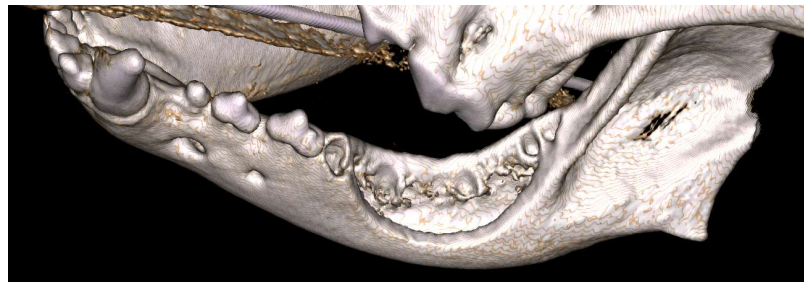
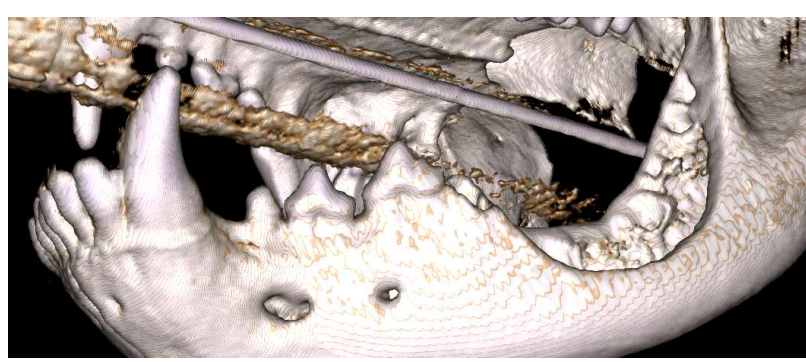


X-ray
After Oral Surgery

X-ray
After Oral Surgery

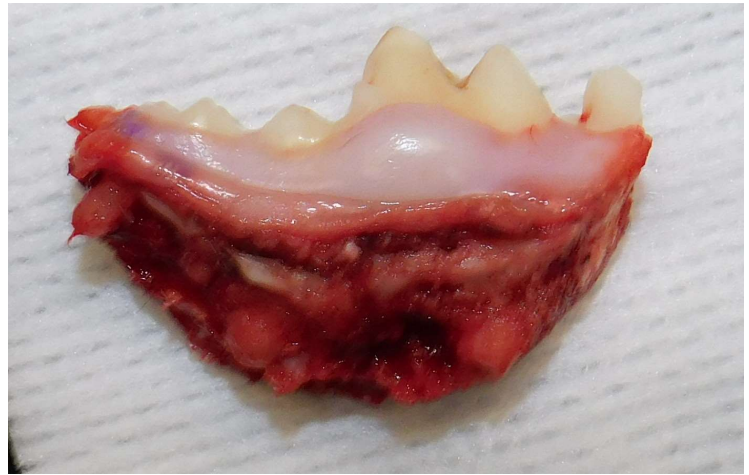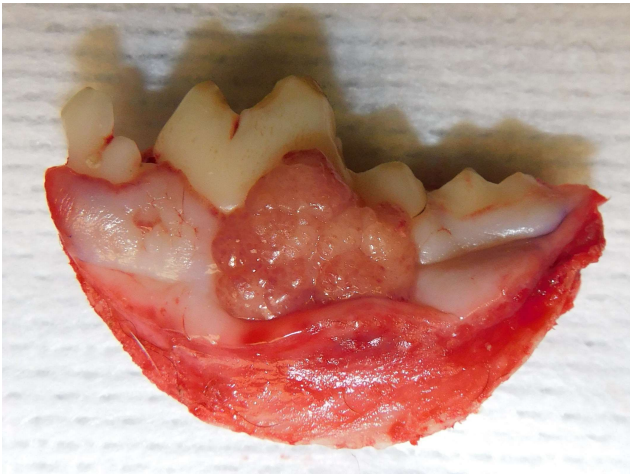
All Pets Dental

Penny (25540) 04-15-2021



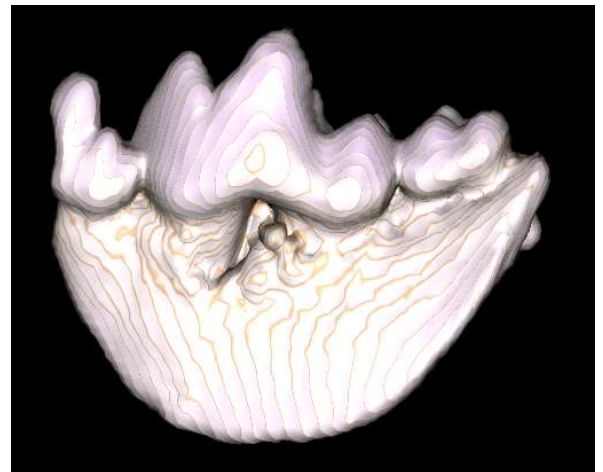
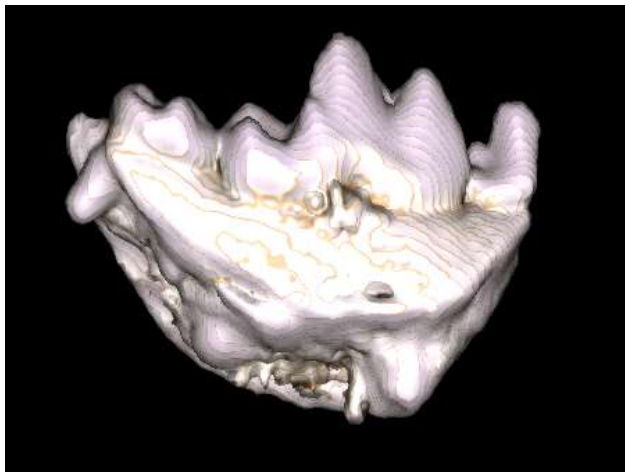
CT
After Oral Surgery

CT
After Oral Surgery



Oral Mass After Removal

Oral Mass After Removal

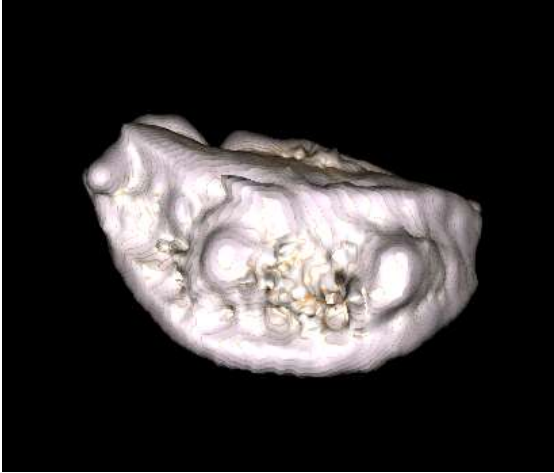

CT
Oral Mass After Removal

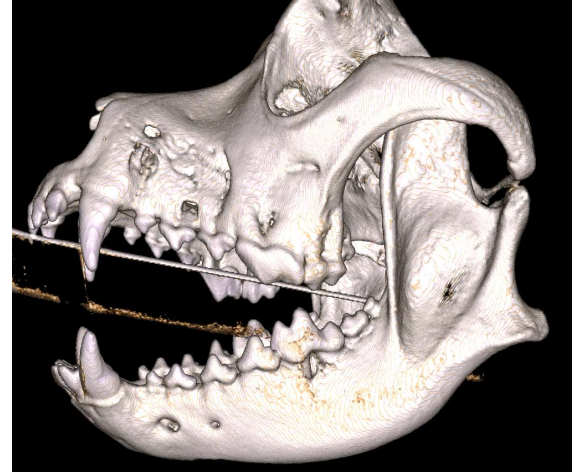
CT
Oral Mass After Removal

All Pets Dental

Penny (25540) 04-15-2021



CT
Oral Mass After Removal



CT
Prior to Oral Mass Removal

All Pets Dental