



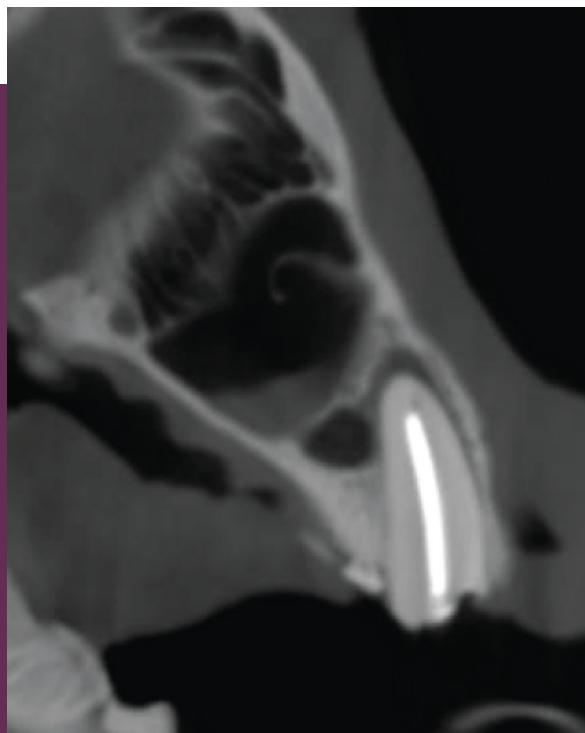
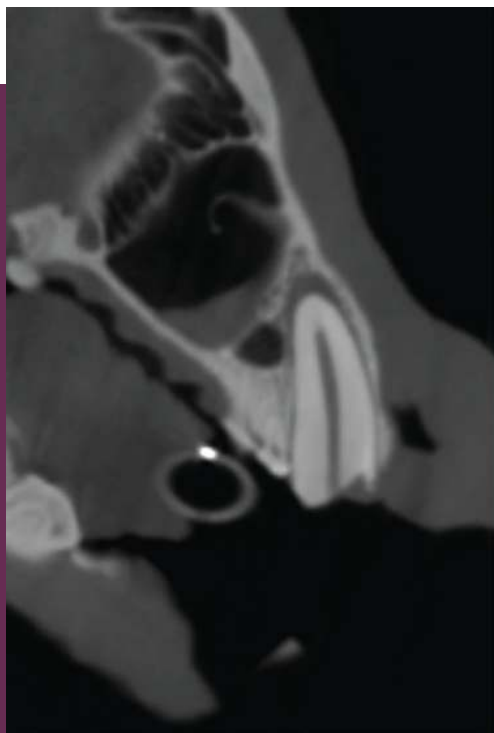
VETCAT PROVIDED CLEAR VISUALIZATION OF EXPOSED PULP, NECROSIS, AND A PERIAPICAL LESION, ENABLING ENDODONTIC THERAPY ON A WOLVERINE

September 2017

A crown fracture on this wolverine resulted in exposure of the pulp, necrosis and periapical lesion.

Endodontic therapy was performed and immediately evaluated using VetCAT.

Courtesy of: Dr. Jamie Berning, Midwest Mobile Veterinary Dentistry, Columbus, OH



Xoran is passionate about helping animals and supporting veterinarians.



800.709.6726 / xorantech.com

VETCAT CASE STUDY #6