

PIEZOTOME CUBE

Extraction of feline mandibular premolar affected by tooth resorption. The Piezotome Cube was used to preform this extraction. Conventional high speed drills were not used. The patient is a 3.5kg domesticated cat.

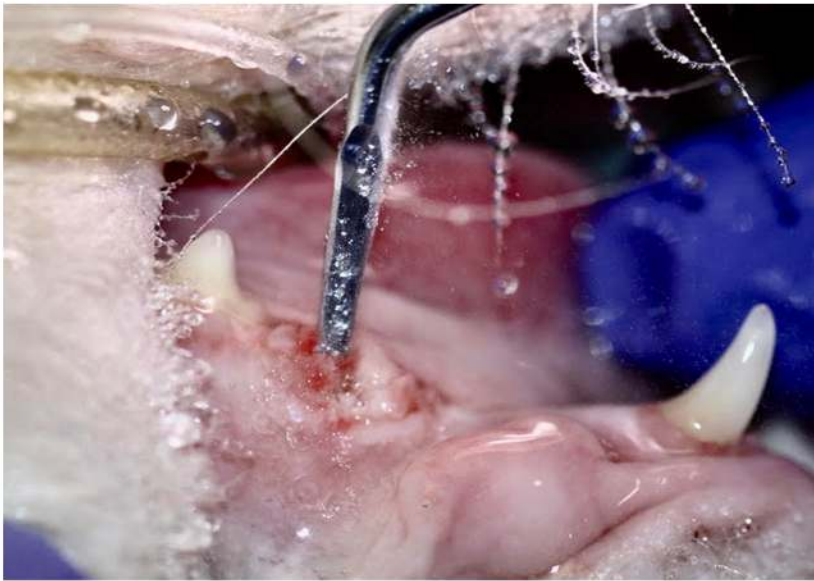

Figure 1.

The Piezotome is used for the extraction of 407.

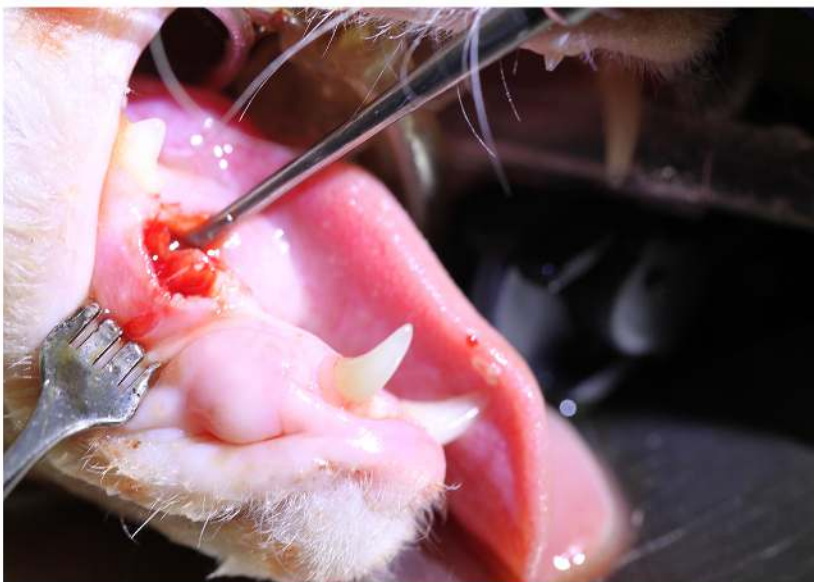


Figure 2.

407 is elevated and then completely extracted.

PIEZOTOME CUBE

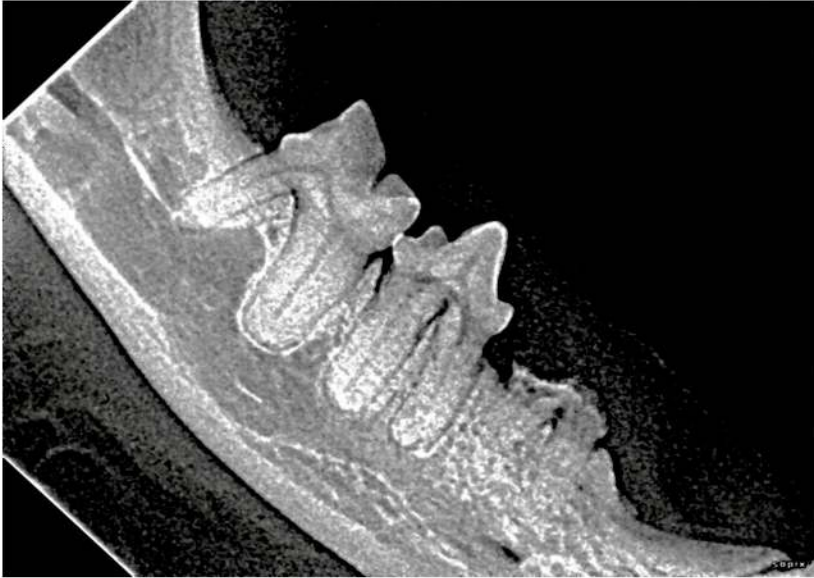

Figure 3

X-ray of 407 revealed stage four tooth resorption. Extraction recommended.

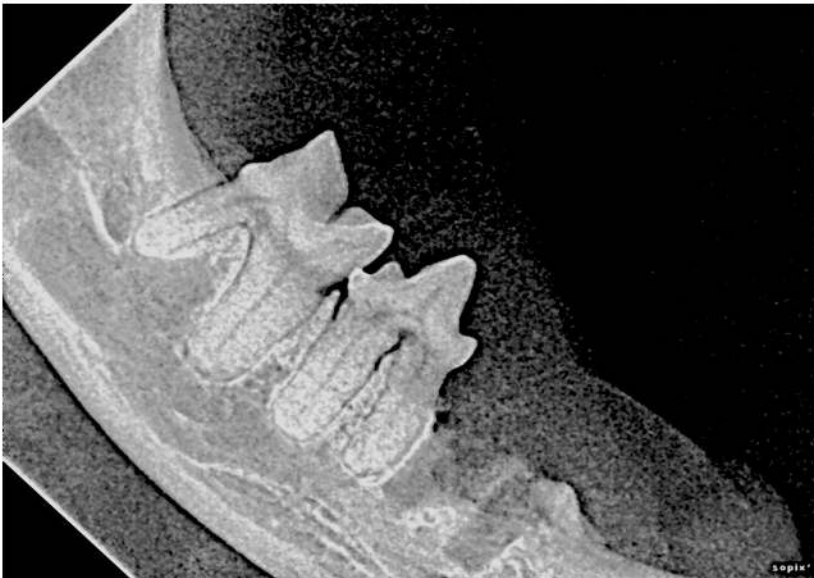

Figure 4

After extraction x-ray confirms complete extraction of 407.

Case study thanks to Dr. Thoulton
Surgeon, DVM, FAVD, DiplAVDC.